

## **Effect of Platelet Rich Plasma (PRP) on Wound Healing in Local Iraqi Arabian Horses**

### **تأثير البلازما الغنية بالصفائح الدموية على التئام الجروح في الخيول العراقية العربية المحلية**

Abbas Ali Hussein AL-LBAN

Department of Surgery and Obstetrics, College of Veterinary Medicine, Al- Qadisiya University, Iraq

Abbas.Ali@qu.edu.iq 07801304489

#### **Abstract**

To evaluate the effects of platelet rich plasma (PRP) on cutaneous regeneration and wound healing in both fixed and movable regions in horses, the present study was undertaken, under local anesthesia a full thickness square incision were done in the back of animals (fixed incision) and the longitudinal full thickness were done in the neck region (movable incisions). The fixed incisions injected 1 cm far from the incision's edges with 0.1 ml of autologous PRP while the control group injected with normal saline only and by same manner the movable incision is treated besides that suturing is applied too. Our results showed that PRP lowered excessive development of granulation tissue and showed wound healing at 1, 2 and 3 weeks after wounding based on the histopathological results, there were re-epithelialization of epidermis, complete healing which characterized by regular arrangement of profuse fibrosis and scattered inflammatory cells, formation of new blood vessels and profuse collagen and fibrosis when compared with control group. We conclude from the current study that the single application of PRP for the treatment of the movable and fixed cutaneous wounds has increased the healing rates and adequate formation of granulation tissue as well as enhance angiogenesis in the beginning stage of the repair process.

Keyword : platelet rich plasma, wound healing, skin, Iraqi Arabian horses

#### **الخلاصة :**

اجريت الدراسة لتقييم تأثير البلازما الغنية بالصفائح الدموية على التجدد الجلدي والتئام الجروح على منطقتين احدهما ثابتة والاخرى متحركة في الخيول ، تم احداث جرح كامل على شكل مربع في ظهر الحيوانات (جرح في منطقة ثابتة ) وجرح كامل اخر بشكل طولي في منطقة الرقبة (جرح في منطقة متحركة ). تم حقن 0.1 مل من البلازما الغنية بالصفائح الدموية لنفس الحيوان على بعد 1 سم من حافة الجرح في حين تم حقن نفس الحجم من المحلول الملحي الفسلجي وب نفس الطريقة في مجموعة السيطرة و بالإضافة الى ذلك تم خياطة الجرح الطولي فقط .

أظهرت النتائج بان البلازما الغنية بالصفائح الدموية قد خفضت التطور الكبير بالنسيج الحبيبي وخلال الفترات 1 و 2 و 3 اسابيع بعد إجراء الجروح ، كما لوحظ بان هناك إعادة للطبقة الطلائية للبشرة وكذلك فان الالتئام الكامل للجروح اظهر ترتيب منظم لفرط التليف وانتشار للخلايا الالتهابية وتكوين الاوعية دموية جديدة و غزارة في التليف والغرين عند مقارنة ذلك مع مجموعة السيطرة .

نستخلص من الدراسة الحالية ان اعطاء البلازما الغنية بالصفائح الدموية لمرة واحدة كعلاج للجروح الجلدية المتحركة والثابتة قد أظهر زيادة في معدل الالتئام وتكوين نسيج حبيبي كاف بالإضافة الى ذلك قد مكن من نشوء الاوعية الدموية الجديدة في المراحل الاولى من عمليات الإصلاح .

الكلمات المفتاحية : البلازما الغنية بالصفائح الدموية ، التئام الجروح ، الجلد ، الخيول العربية العراقية .

## **Introduction**

Horse mostly suffers from traumatic wounds and healing of these wounds take long period and many complications when compared with others species(1). Skin lesions in horses are relatively frequent and healing required long recovery period and may lead to chronic wound or exuberant tissue granulation. These results are more frequent in large wounds on limbs and in each other anatomical region subject to motion , such as wounds of the trunk or head usually heal uneventfully(2).

Wound healing depends on several, jjm factors in animals, such as blood supply , tension and mobility of wound margins , size of wound susceptibility to infection, type and condition of underlying tissue(3). Other factors like advanced age , malnutrition and diseases such as diabetes can negatively influence the healing process(2). A sequence of events regulate this process including coagulation, inflammation, formation of granulation tissue, epithelialization and tissue remodeling. These processes mediated by interacting molecular signals primarily on the part of cytokines and growth factors(4).

Growth factors are important for regulating the cellular events involved in healing of wound. Clinical study shows that growth factors treatment accelerates healing of normal tissues and promotes healing of impaired wounds (5).

Platelet rich plasma(PRP) is a concentrate of growth factors and cytokines released from platelet alpha granules at the site of injury, releasing of growth factors occurs after platelet degranulation, including platelet, derived growth factor, transforming growth factor B and vascular endothelial growth factor. These growth factors have many affections such as fibroblast recruitment and proliferation and matrix remodeling , induce chemotaxis of neutrophil and monocyte in the wound site and a vascular permeability factor which influence extravasations of plasma protein creating a support for epithelial and endothelial cells respectively(4).

The platelets act in the homeostasis, re-epithelialization and wound healing librating growth factors that stimulation angiogenesis, promoting growth and vascular fibroblast proliferation that provide an increase in the collagen synthesis(6). Platelets rich plasma is an autologus product which has multiple cytokines release from platelets alpha granules(7). Platelet rich plasma is 100% safe and biocompatible. It has absolutely no infections risk to the patient because it is made from the patient's own plasma.

Many studies have been done on different animals for investigation of healing process by applying PRP (8, 9 and 10) And due to little researches in local breeds horses of middle Euphrates so that we have a scientific reason to find out the action of PRP on experimental incisions. This study aimed to describe an alternative to traditional treatment that could be considered is similar clinical cases to accelerate a physiological mechanism of healing by applying platelet rich plasma around the experiment incisions .

## **Materials and methods**

### **Experimental animals :-**

The study is conducted on 8 local Iraqi Arabian horses, their ages were  $7.5 \pm 0.5$  years old, and their weights were  $450 \pm 50$  kg., 2 stallion and 6 mares. All of them are fed on grain, alfa- alfa, and straw at standard quantity with drinking water *ad libitum*.

### **Experimental design:-**

The experimental horses were divided randomly and equally into 4 groups: treatment group-1(TG1), treatment group-2(TG2), control group-1(CG1) and control group-2(GC2).

Horse platelet rich plasma (PRP) was prepared by manual method which prescribed by(11), including collecting 60 ml of equine whole blood through a single jugular venipuncture with 18 – gauge needle under sterile condition before the surgical procedures, the blood was deposited in heparinized tubes. The tubes were centrifugated at  $72 \times g/15 \text{ min}$ , promoting the separation of the plasma. Plasma with the platelets remained in the superior portion, after that plasma was drawn by

sterile plastic transfer pipette to another sterile plastic tube . The superior portion of each tube and centrifuged again at 100 xg for 5 minutes. This procedure produced approximately 6 ml of PRP .

Under routine local anesthetic infiltration by lidocaine 2%. Skin preparation protocol included hair shaving and povidone iodine scrubbing were done and the horse were sedated with xylazian(2.2mg/kg).

A full thickness square incisions (3x3cm)were done in the back of animals(fixed incision) in TG1 and CG1,while the longitudinal full thickness incisions were done in the neck region (movable incision) of TG2 and CG2. The horses were kept under close observation for several hours after incisions and checked for the first week for any complication may be detected.

By automatic intradermal syringe; TG1 and TG2 were injected 1cm. far from the incisions' edges,(0.1) ml. of autologous PRP) in each injection infiltrated along the incision' edges, then only the incisions in the TG2 and CG2 were sutured with simple interrupted pattern with silk no.1. At the same manner of injection the CG1 and CG2 had treated with normal saline only.

### **Histopathological study:-**

After 1, 2, and 3 weeks post operations the horses were sedated with xylazine 2.2ml and the incisions sites were cleaned with normal saline and sterile gauze. The biopsies were taken from all incisions and put in formalin 10% for histopathological examinations to evaluate the healing processes.

### **Results :**

No clinical complication are observed in the incision healing in any animal, and in order to evaluate the structural organization of collagen in the dermis of all surgical wounds, the biopsies were taken at 1, 2, 3 weeks postwounding.

There is purulent exudates characterized by presence of neutrophils and cellular debris along the epidermis and dermis as in Fig.1. The second longitudinal treatment group TG2 at the end of 1<sup>st</sup> week shows a presence of homeostasis in the site of wound with fibrin network, while the CG2 showed a thickness of epidermis, noticeable profused fibrous connective tissue and mild infiltration of inflammatory cells mainly macrophage are seen in the dermis as in Fig.2 and 3. PRP treated square surgical wounds TG1 obtained at day 7 postwounding displayed there is a downward hyperplasia of stratum basali and profused granulation tissue which characterized by high proliferation of endothelial cells and fibroblast. Furthermore, presence of pus formation in which cellular debris and dead neutrophils Fig.4 and 5, when compared with control group CG1 which showed an evidence of hyperplasia with thickening of epidermis as well as highly infiltration of cells in the site of wound, profuse fibrous connective tissue , also there is a mild infiltration of inflammatory cells and the hyperkeratosis as in figure Fig.6.

While the CG1 has semilike progression of epithelialization except there is a presence of severe hemorrhage in the demis Fig.7. The CG2 showed a presence of surgical wound, a mild downward hyperplasia in the basal cells of epidermis, besides that there is a mild infiltration of inflammatory cells as in Fig. 8 .

Fourteen days post-wounding of the TG1 refers to downward hyperplasia of stratum basali and profused fibrosis as well as there is a noticeable infiltration of inflammatory cells and formation of new blood vessels as in Fig.9 .

The TG2 of the same previous mentioned period, there is a downward hyperplasia of stratum basali of epidermis with presence of collagen and formation of new blood vessels with fibrosis also there is a formation of new and small hair follicles and sweat glands as in Fig.10. The CG1 showed narrow surgical wound with presence of collagen fibers and irregular arrangement of fibrosis,infiltration of inflammatory cells with destruction of keratinized layer as in Fig.11. The CG2 reveals a thickening and hyperplasia of epidermis with highly profuse fibrosis and infiltration of inflammatory cells as in Fig.12 and 13.

A PRP-treated square wound TG1 obtained at day 21 post-wounding displays there is a profuse of fibrous connective tissue and formation of new blood vessels by proliferation of endothelial cells,

also there is a mild aggregation of inflammatory cells, hyperplasia of epithelial cells of epidermis and thick keratinized layer as in Fig. 14 and 15.

The figure obtained in the histological view of TG2 at 3<sup>rd</sup> week post-wounding shows there is a complete healing which characterized by proliferation of epidermal cells and regular arrangement of profuse fibrosis with scattered inflammatory cells formation of new blood vessels as in Fig.16 .



Fig.(1): hyperplasia with thickening of epidermis( → ), highly infiltration of inflammatory cells in the site of wound( → ) with profuse fibrous of connective tissue in the dermis( → ). Also there is purulent exudates characterized by present of neutrophils and cellular depress along the epidermis and dermis ( → )(20X.H&E)

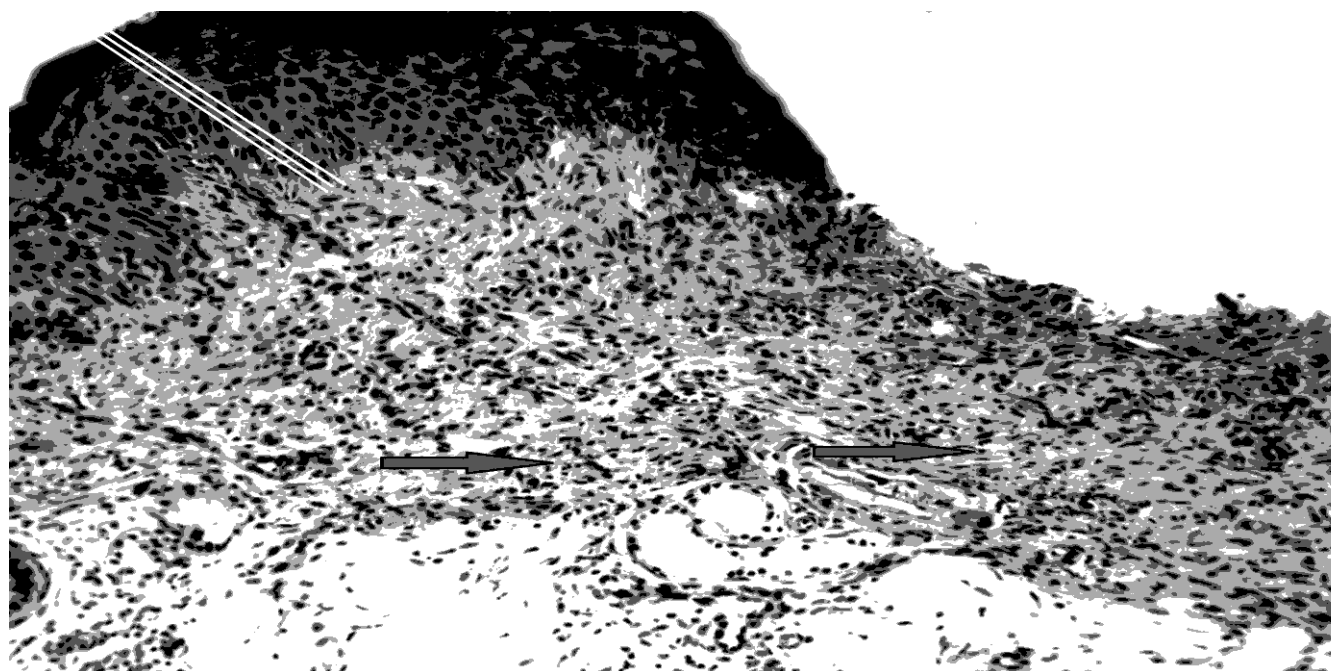


Fig.(2): Thickening of epidermis(white lines) and profuse fibrous connective tissue in the dermis( → ) (20XH&E) .

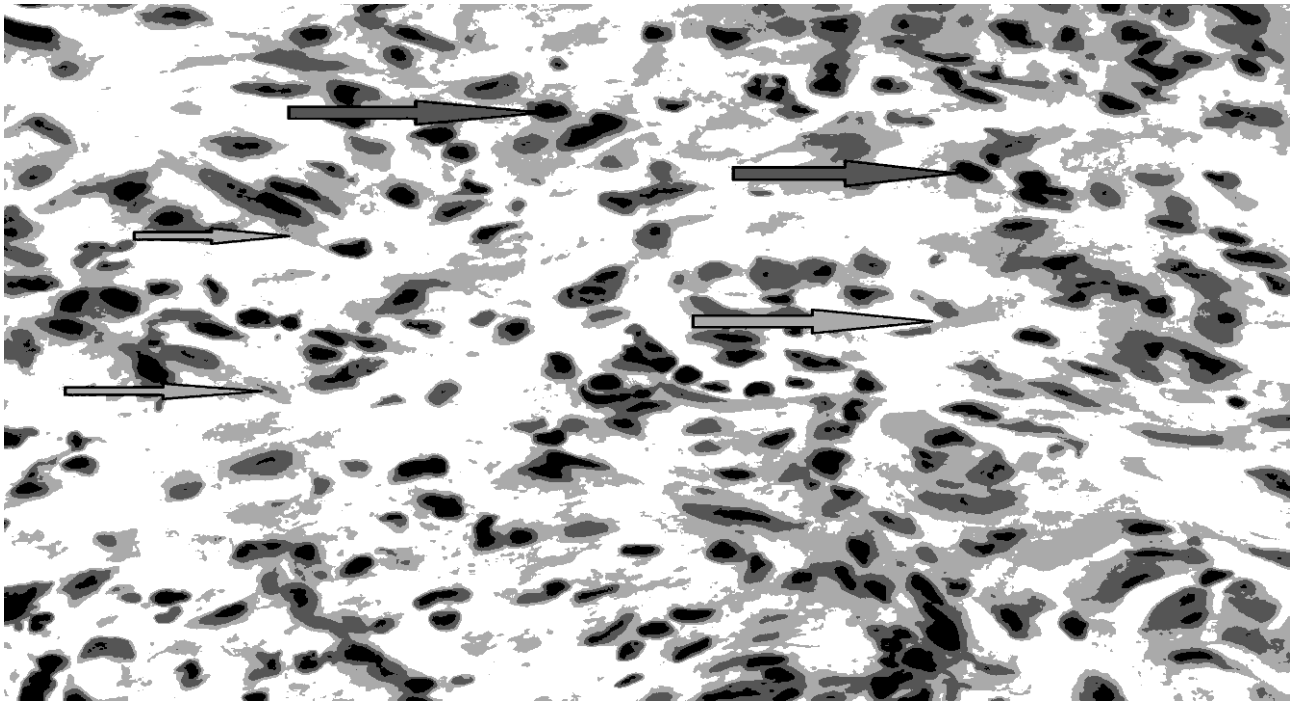


Fig.(3): Profuse fibrous connective tissue(→) mild infiltration of inflammatory cells mainly macrophage in the dermis(→)(pink arrow)(200XH&E) .




Fig.(4): Downward hyperplasia of stratum basali(→) profuse granulation tissue which characterized by high proliferation of endothelial cells and fibroblast(→) and presence of pus formation in which cellular debris and dead neutrophils(→) (200XH&E) .



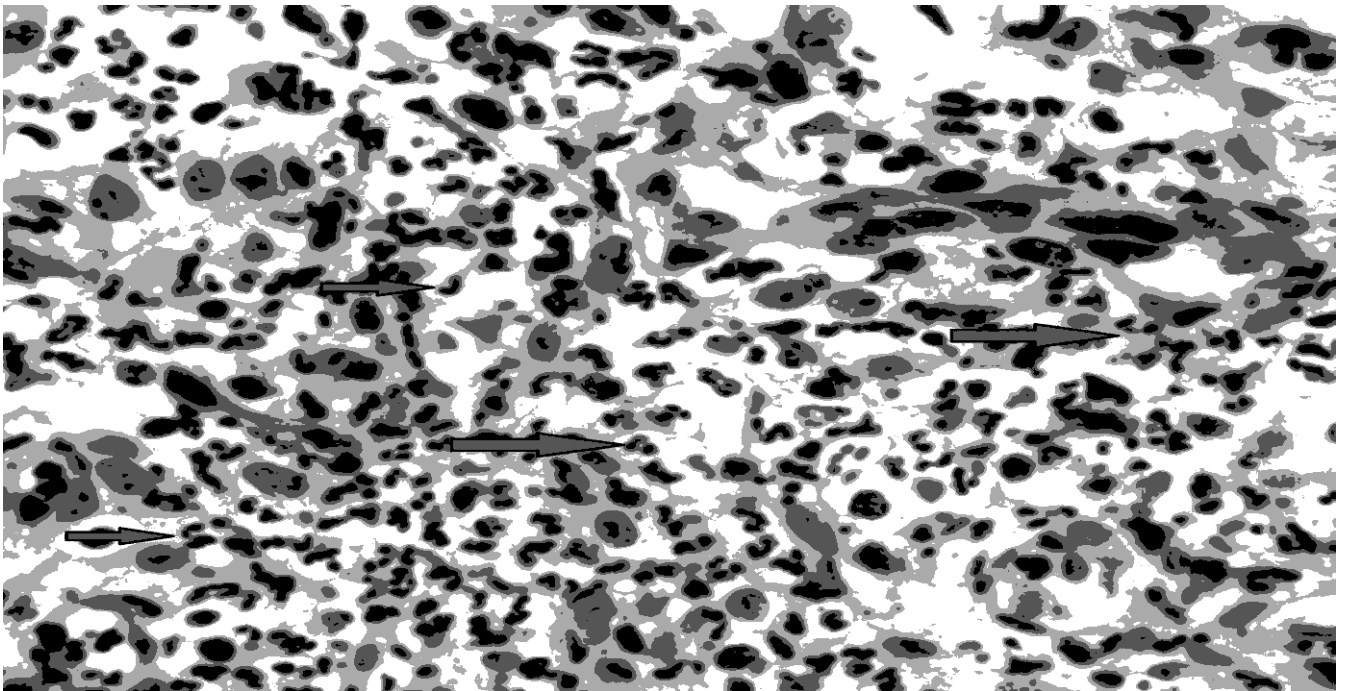


Fig.(5): Purulent exudates characterized by abscess formation in which cellular debris and dead neutrophils( →)(200X H&E).

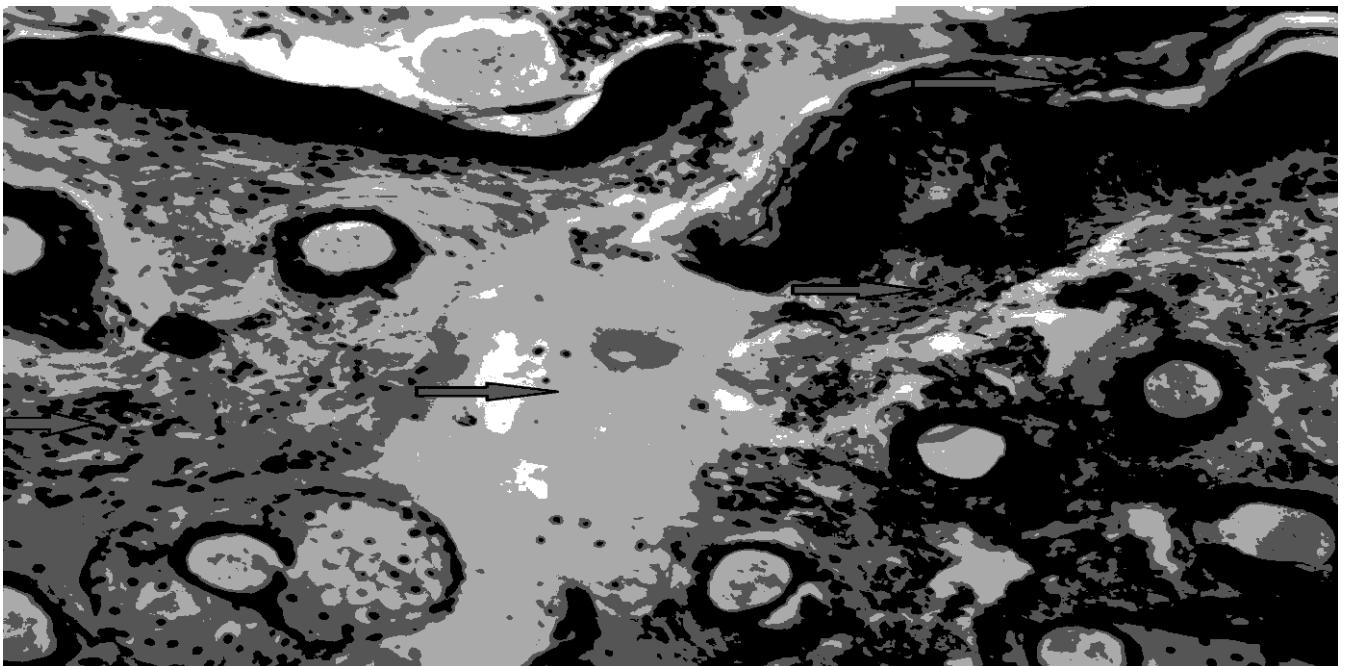


Fig.(6): Present of homeostasis in the site of wound with fibrin network( →)and mild infiltration of inflammatory cells ( →) also there is hyperkeratosis( →)(20X.H&E) .

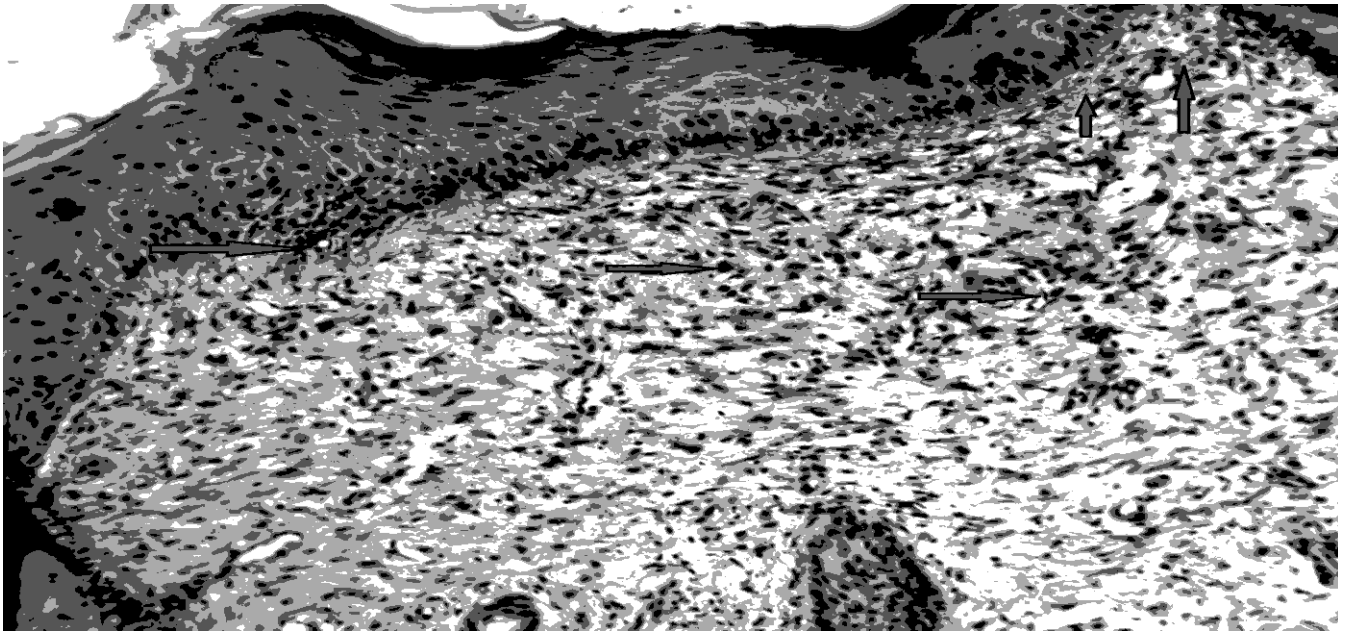


Fig.(7): Downward hyperplasia of stratum basali(→) and infiltration inflammatory cells(→)with profuse fibrosis in the dermis with presence of severe hemorrhage in the dermis (→)(50XH&E).

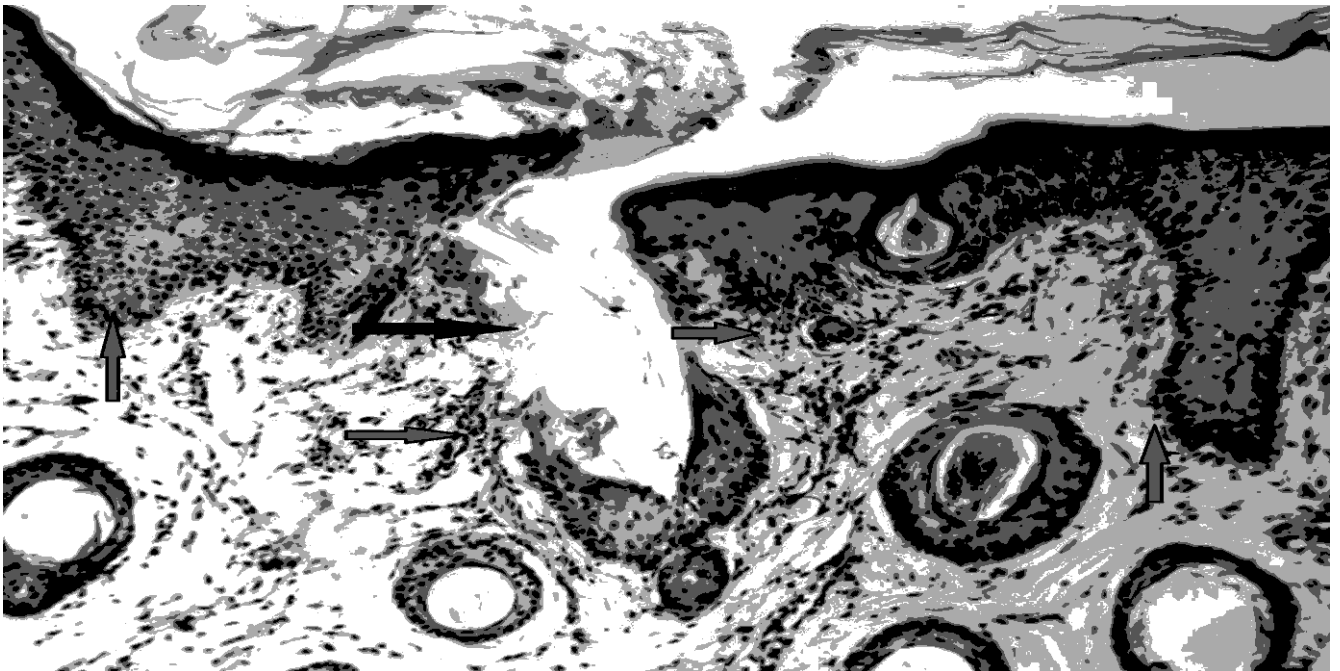


Fig.(8): Presence of surgical wound(→) also there is mild downward hyperplasia in the basal cells of (→) also there is mild infiltration of inflammatory cells(→)(50X H&E) .

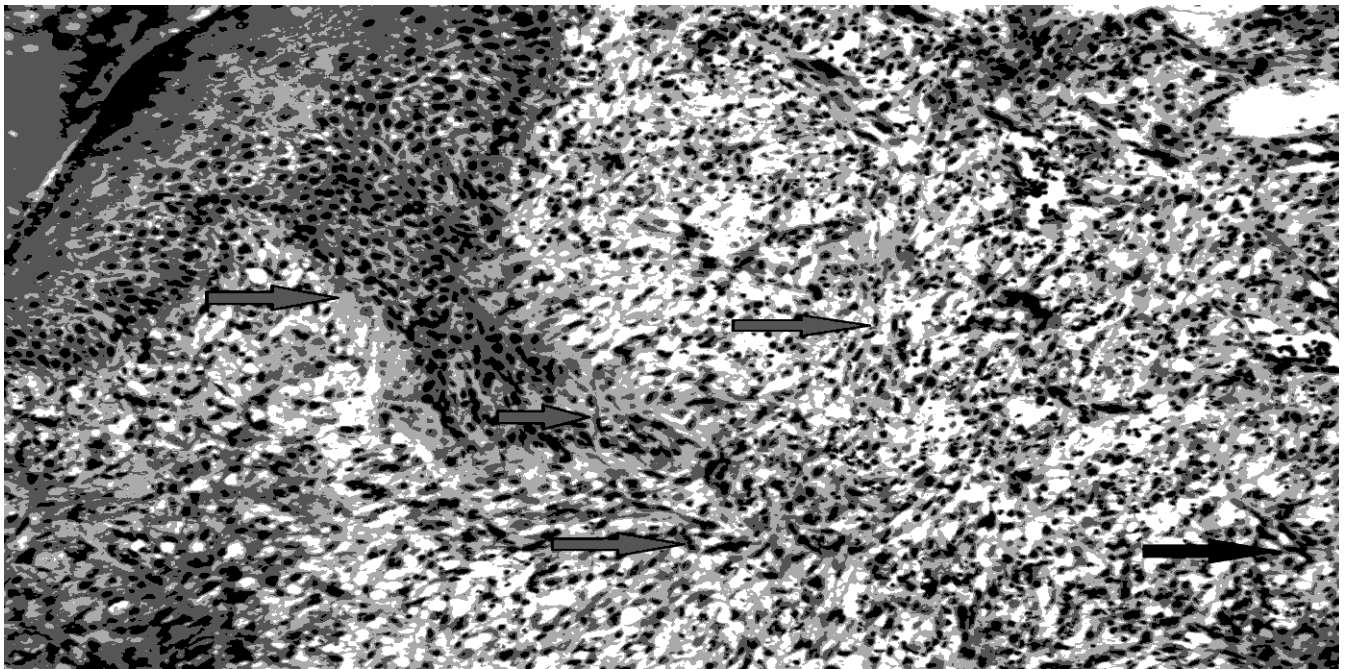


Fig. ( 9 ) : Downward hyperplasia of stratum basali( → ) profuse fibrosis infiltration of inflammation cells( → ) formation of blood vessels( → )(50XH&E) .

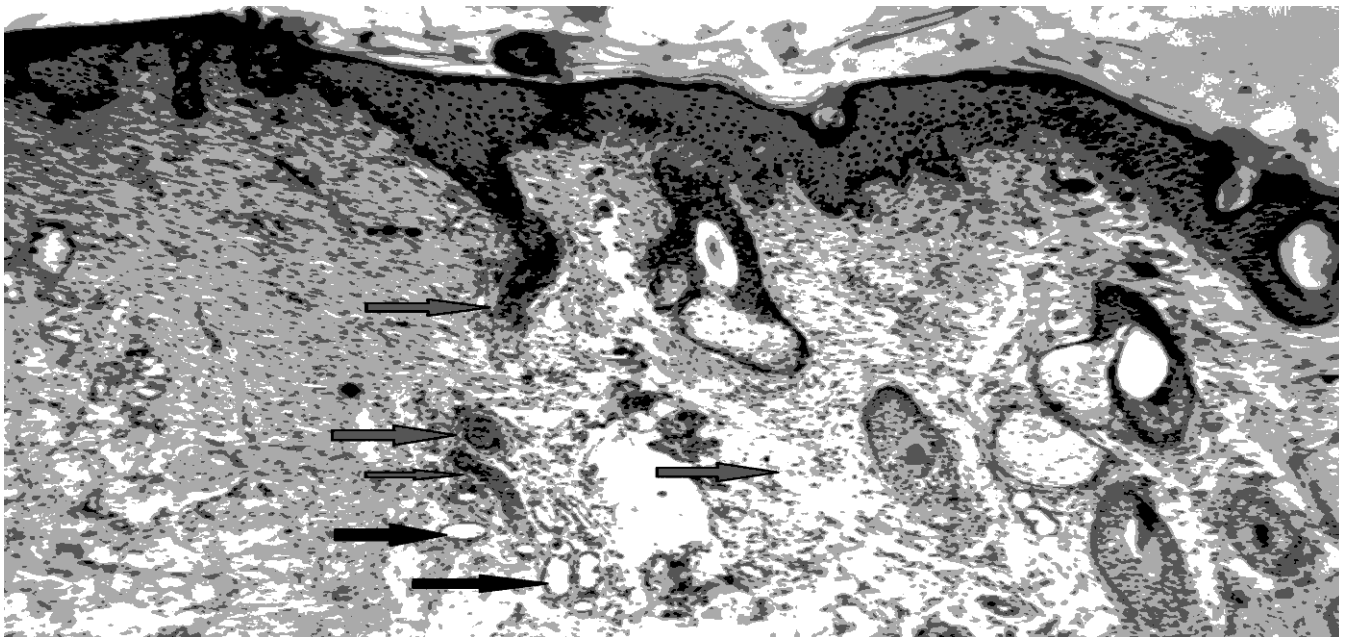


Fig.(10):Downward hyperplasia of stratum basali(→)of epidermis with presence of collagen and formation of new blood vessels( → ) with fibrosis( → ) , formation of new and small hair follicles and sweets gland ( → )(20XH&E) .



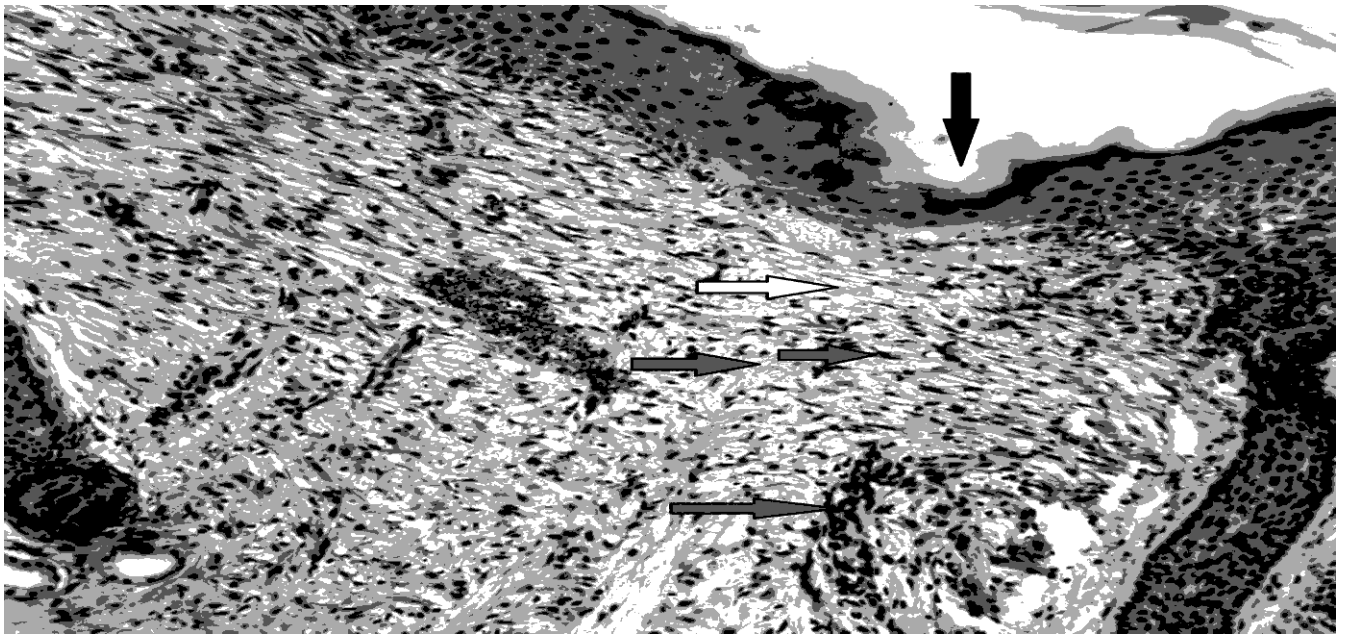







Fig.(11) Narrow surgical wound( ) with presence of collagen fibers( ) and irregular arrangement of fibrosis( ) infiltration of inflammatory cells( ) with destruction of keratinized layer ( )10x(H&E).

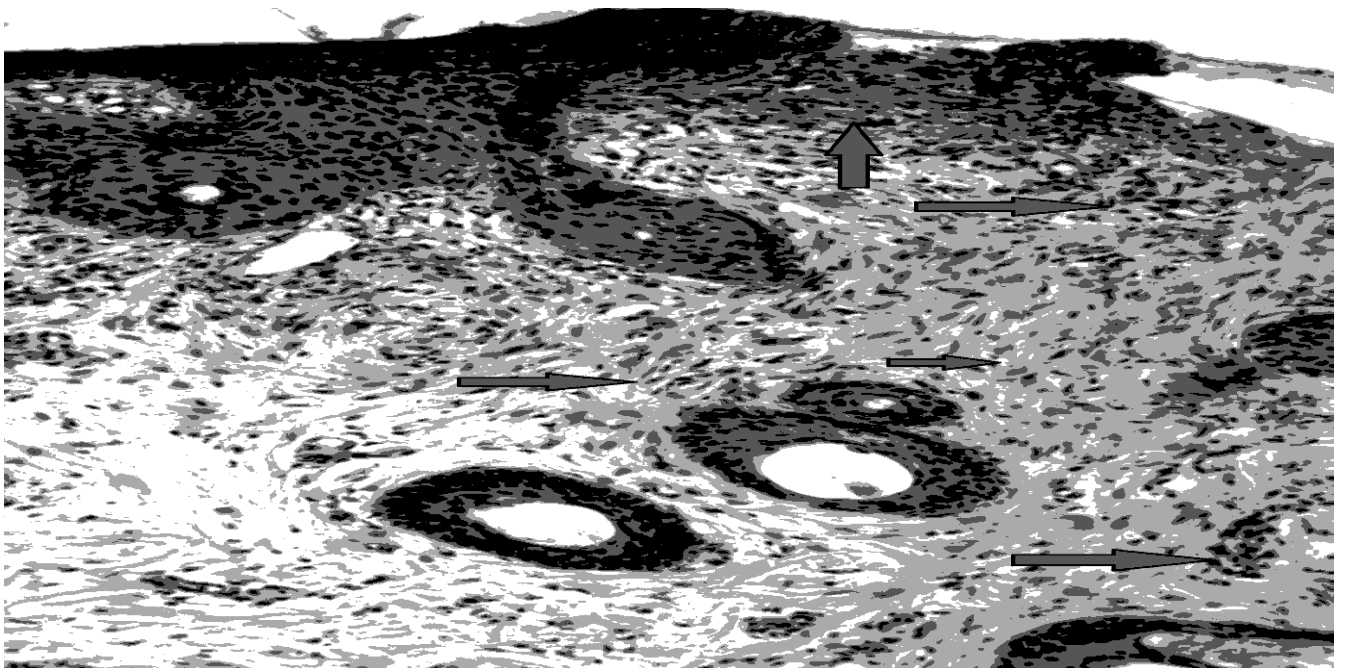





Fig.(12): Thickening and hyperplasia of epidermis( ) with highly profuse fibrosis( ) with infiltration of inflammatory cells( ) (50XH&E) .

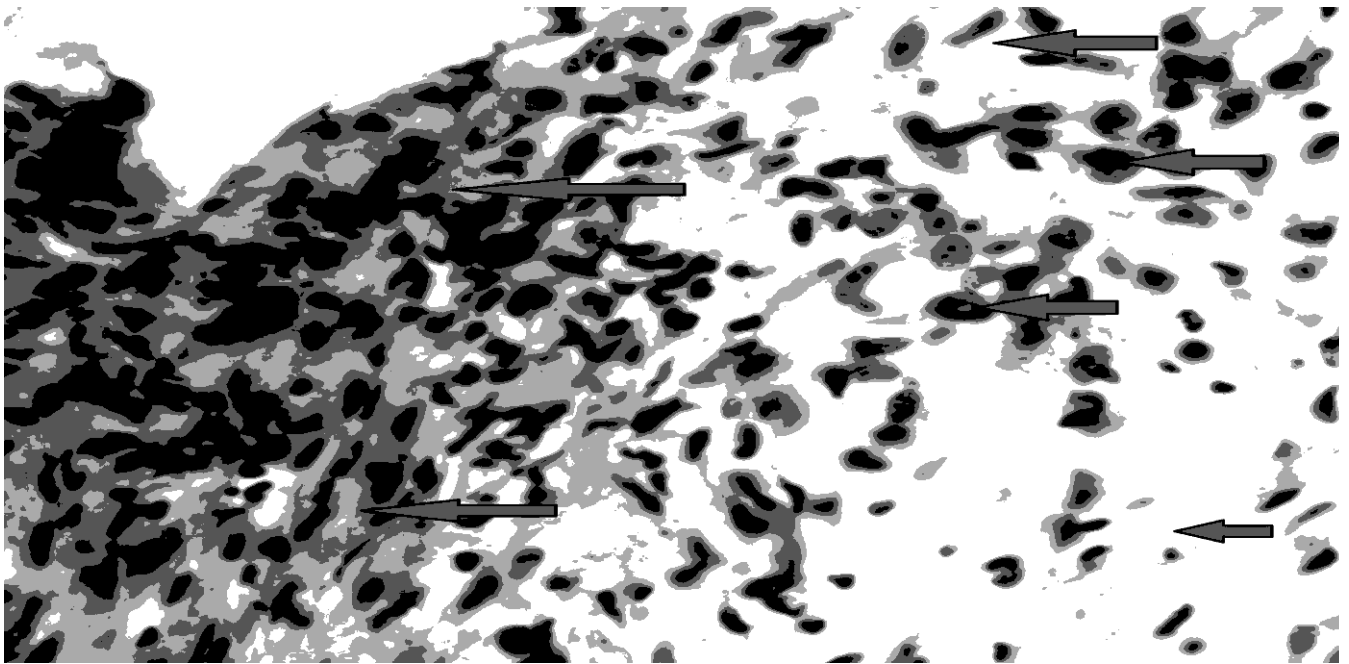


Fig.(13): Thickening and hyperplasia of epidermis( → ) with highly profuse fibrosis( → ) with infiltration of inflammatory cells( → )(50XH&E) .

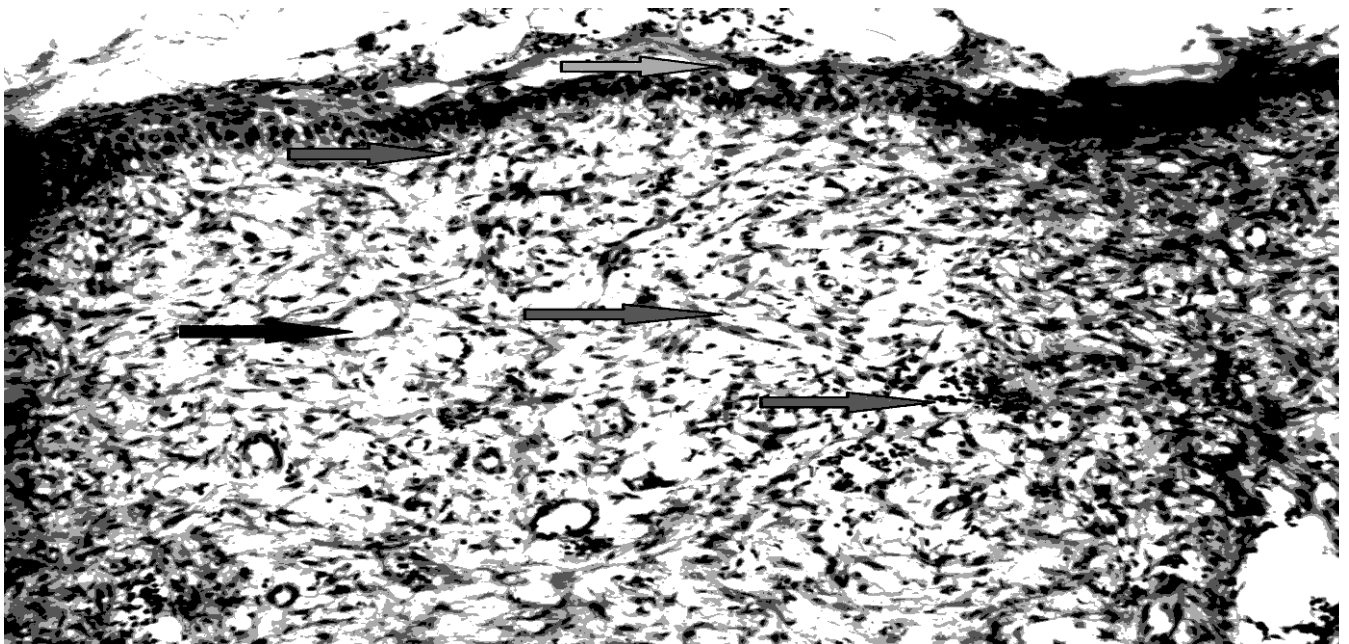


Fig . ( 14 ) : Profuse fibrous connective tissue(→) and formation of new blood vessels ( → ) ,mild aggregation of inflammatory cells( → ) also there is hyperplasia of epithelial cells of epidermis ( → ) and thick keratinized layer also present( →)(20XH&E).



Fig . ( 15 ) : There is proliferation of fibroblasts( → ), and proliferation of endothelial cells to form new blood vessels( → ) mild aggregation of inflammatory cells also there is hyperplasia of epithelial cells of epidermis( → )(200XH&E) .



Fig . ( 16 ) : Complete healing which characterized by proliferation of epidermal cell(→)and regular arrangement of profuse fibrosis(→) scattered inflammatory cells ( → )formation of new blood vessels(→ )(50XH&E).

**Discussion :**

The period which required for the closure of a cutaneous incision depends on the presence of local infection and on the extent and anatomic location of injury (movable or fixed). The wound healing process of skin surface in horses is reepithelialized with dermis healing by stromal granulation, migration of myofibroblasts and wound contraction (12). The skin wound healing progress is classically divided into four well-defined phases, containing hemostasis, inflammation, proliferation and remodeling (13,14). The third phase may be subdivided into migration and proliferation, and the fourth phase into contraction and remodeling (15).

A new wound healant composed of PRP is delivered as a topical application to cutaneous incisions in the local horses in the mid-Euphrates region. PRP accelerates epithelial differentiation in squarical biopsies from equine incisions. Additionally, the PRP treated tissues is organized as dense, tightly packed fiber bundle parallel to overlying epidermis, whereas control tissues exhibited little collagen fibers arranged randomly. The organized, dense collagen suggests increasing the tensile strength in the repaired wound.

The PRP is a product that induces a wound healing acceleration of difficult to heal wound (16). The initial phase of the healing is mediated by growth factors secreted by the platelets, the latter is activated with thrombin (17). Cutaneous incision healing involves repair and regeneration and these are controlled by growth factors which regulate protein expression, enzyme production, differentiation of cells, proliferation, metabolism, and migration, also the synthesis and remodeling of extracellular matrix (18).

The results of fixed wound region which attained by the present study accord with (10) who found that the local injection of PRP lead to accelerate and improve the wound healing in the lateral thoracic region in comparison to control wounds.

On the other hand, the results of movable wound region were obtained by this study disagreed with (19) who found that the wound healing of distal part of limbs in horses treated by PRP and platelet rich growth factor revealed there were granulation tissue formation, wound exudation; and these may be due to the ages of the horses in the study was so aged when compared with the ages of the present study as well as the incision in the recent study sutured.

The application of PRP on the incisions in the neck region has the same results and agreed with (20) who explained that wounds treated with PRP gel has more rapid epithelial differentiation and enhanced organization of dermal collagen compared to control groups in horses.

Furthermore, the wound created surgically in the right and left gluteal regions treated with single local administration of PRP resulted in important immunohistochemical expression of collagen which remains high even during the macroscopic closure of wounds (21) and this accord with the present results of the movable wounds.

In one study done on black Bengal goats exposed to an incisions on the skin and treated with PRP showed excellent results in the healings of skin and the histopathological study demonstrated a new hair follicular growth in healed area with 5 days (9) and this has concurrence with the recent results.

The novelty of PRP and its more recent discovery, has been found to be effective in healing of a chronic wound (22) also (23) found that autologous PRP in the ulcer revealed there was no local infection or other complications, as well as (24) showed that application of PRP in the neuropathic ulcers exhibited that PRP was more likely to be used in more severe wounds and was also more effective in treating these wounds than the standard of care.

Application of PRP in cutaneous regeneration and wound healing in dogs conducted by (8) who revealed that there were no significant differences between median of epithelialization, inflammatory cell infiltration, presence of dermal granulation tissue, fibroblast arrangement, fibroblast proliferation, collagen deposition in the both of treated and non-treated wounds and this disagreed with what conducted by the present results of the study and this due to the species of animal may have this effect and/or the cutaneous wound of the dogs of the previous study was treated with dexamethasone.



The recent study achieved to show the effect of PRP on the healing of acute wounds in rabbits displayed that the PRP treated group enhanced angiogenesis at the wound beds as compared to control group(25) and this has agreement with the present study.

The results of this study reveal that confirm observation from the basic science of incision repair a positive charges in incision variable are seen following application of PRP, these findings are most important because PRP injection remain the main standard for determination of treatment efficacy(26).

Furthermore, it is revealed that the benefits of topical PRP application for the treatment of the movable and/or fixed cutaneous wounds exhibit faster healing rates and adequate formation of granulation tissue when compared with wound treated with normal saline .

In addition, the topical use of PRP application has been shown to enhance angiogenesis in the beginning stage of the repair process after incise the skin and subsequently to promote healing of incision. Under optimal clinical conditions, the autologous PRP can accelerate healing of both fixed and movable incisions, because the biological preparation is a vector for cell growth factors.

## **References**

- 1) Wilmlink J M and Weeren R.(2004). Differences in wound healing between horses and ponies: application of research results to clinical approach of equine wounds. *J Clinical techniques in equine practice* 3:123-133.
- 2) Crovetti G, Martinelli G, Issi M, Barone M, Guizzardi M and Campanati B. (2004). Platelet gel for healing cutaneous chronic wounds. *Transfus Apher Sci*;30:145-151
- 3) Knox RL, Hunt AR, Collins JC, DeSmet M and Barnes S.(2006). Platelet-rich plasma combined with skin substitute for chronic wound healing:a case report. *J Extra Corpor Technol*;38:260-264.
- 4) De Rossi R, Coelho AC, Mello GS, Frazílio FO, Leal CR, and Facco GG. (2009).Effect of platelet-rich plasma gel on skin healing in surgical wound in horses. *Acta Cir Bras*;24:276-281.
- 5) Carter AC, Jolly DG, Worden CE, Hendren DG, and Kane CJM.(2003). Platelet-rich plasma gel promotes differentiation and regeneration during equine wound healing. *Exp Mol Pathol*.74:244-255.
- 6) Marx RE.(2004).Platelet-rich plasma: evidence to support its use. *J Oral Maxillofacial Surg*;62:489-496.
- 7) Steven P, Demetris D, and Scott AR.(2011). What is the platelet rich plasma? *J Operative technique in sport medicine*;19:142-148.
- 8) Sardari K, Emami MR, and Kazemi H. (2011). Effects of platelet-rich plasma (PRP) on cutaneous regeneration and wound healing in dogs treated with dexamethasone. *Comp Clin Pathol* 20(3):155-162.
- 9) Ferdousy, R. N., Mizanur Md, Sattwikesh S. and Md. Abu.(2013). Role of platelet rich plasma gel in the wound healing of Black Bengal goat. *IOSR-JAVS* 6(5): 14-21.
- 10) AL-Bayati AH, Al-Asadi RN, and Mahadi AK.(2013).Effects of autologous platelets rich plasma on full-thickness cutaneous wounds healing in goats. *Int J Anim Veter Adv* 5(6): 233-239.
- 11) Monterio SO, Lepage OM, and Theoret CL.(2009).The effect of plateletrich plasma on the repair of wounds on the distal aspect of the forelimb in horses *Am J of veterinary research* 70:277-282.
- 12) Greenwood, J. E. (2010). Function of the panniculus carnosus-a hypothesis,” *The Veterinary Record* 167(19) p. 760.
- 13) Enoch S. and Leaper, D. J. (2005).Basic science of wound healing,*Surgery*. 23(2) pp. 37–42.
- 14) Young A. and McNaught, E.(2011).The physiology of wound healing, *Surgery*, 29 (10) pp. 475–479.
- 15) Schultz G. S., Davidson J. M., Kirsner R. S., Bornstein P., and Herman, I. M. (2011). Dynamic reciprocity in the wound microenvironment,*Wound Repair and Regeneration*, 19(2), pp. 134–148.

- 16) Robson MC.(1997).The role of growth factors in the healing of chronic wounds.Wound Rep Regenerat.5: 7 -12.
- 17) Strukova SM, Dugina TN, Chistov IV, Lange M, Markvicheva EA,Kuptsovas S, Zubov VP, and Glusa E.(2001).Immobilized thrombin receptor agonist peptide accelerates wound healing in mice. Clin Appl Thromb Hemost.7:325-329.
- 18) Komarcevic A.( 2000).The modern approach to wound treatment. Med.Pregl. 53, 363–368.
- 19) Moradi O, Ghamsari S M, and Dehghan M M. (2013). Effects of Platelet Rich Plasma (PRP) and Platelet Rich Growth Factor (PRGF)on the Wound Healing of Distal Part of Limbs in Horses IJVS 8(1); 41-48.
- 20) Rafael D. R., Anna C. A. and Gisele S. M.(2009).Effects of platelet-rich plasma gel on skin healing in surgical wound in horses.Acta Cirúrgica Brasileira. 24 (4) 276-281.
- 21) Souza M V, Silva M B, Pinto J O, and Lima M B S.(2015) Immunohistochemical Expression of Collagens in the Skin of Horses Treated with Leukocyte-Poor Platelet-Rich PlasmaBioMed Research International.15(12):1-12
- 22) McAleer JP, Sharma S, Kaplan EM, and Persich G.(2006).Use of autologous platelet concentrate in a nonhealing lower extremity wound. Adv SkinWound Care.19(7):354-63.
- 23) Salemi S, Rinaldi C, Manna F, Guarneri GF, and Parodi PC.(2008). Reconstruction of lower leg skin ulcer with autologous adipose tissue and platelet-rich plasma. J Plast ReconstrAesthet Surg.61(12):1565-1567.
- 24) Margolis DJ, Kantor J, Santanna J, Strom BL,and Berlin JA.(2001) Effectiveness of platelet releasate for the treatment of diabetic neuropathic foot ulcers. Diabetes Care. 24(3):483-488.
- 25) Ostvar O, Shadvar S, Yahaghi E, and Azma K. (2015).Effect of platelet-rich plasma on the healing of cutaneous defects exposed to acute to chronic wounds: a clinico-histopathologic study in rabbits Diagnostic Pathology 10(85)1-6.
- 26) Carter MJ, Fife CE, Walker D, and Thomson B.(2009).Estimating the applicability of wound care randomized controlled trials to general wound-care populations by estimating the percentage of individuals excluded from a typical wound-care population in such trials. Adv Skin Wound Care. 22(7):316–324.